

**PATIENT**

Sophia Jones

**SPECIES**

Canine

**BREED**

Pitbull Mix

**SEX**

Female Spayed

**AGE**

6.16.15

**WEIGHT**

65.4lbs

**PRESENTING CLINICAL SIGNS**

History: Vomiting. Lethargic. Decreased appetite since end of July. Restless, shivering. drinking increased, energy decreased. Free fluid in abdomen.

-Pertinent abnormal PE/Chem/CBC/UA Results: phosphorus 5.1 (high), total protein 4.4 (low), glucose 134 (high), ALT 206 (high), ALP 361 (high)

-Current medications: Cerenia SQ 3mL

-Sedation used: Not required to complete full diagnostic ultrasound.

-Pertinent previous ultrasound results: No previous.

-STAT: Declined at the time of the scan.

-Imaging performed by: Stephanie Warga RDCS, RVT.

**ECHOCARDIOGRAM FINDINGS**

2D, m-mode, color flow and doppler imaging is available. Mild thickening of the anterior leaflet of the mitral valve with no obvious prolapse into the left atrial lumen. No mitral regurgitation with normal left atrial dimension. Decreased LV diameter with adequate myocardial function. Increased LV wall thickness. Tricuspid valve appears normal, no TR. Collapse of the RA consistent with tamponade. No obvious tumor in the RA or right auricle. No obvious tumor in the AV groove; however, this is not definitive. The pulmonic and aortic valves are normal in morphology and mobility. Normal pulmonic and aortic outflow velocities; laminar flow. Large volume pericardial effusion. No pleural effusion seen.

**CARDIAC CHART****INTERPRETED BY**

Maggie Machen Lamy,  
DVM, DACVIM  
(Cardiology)

**HOSPITAL NAME**

Alexander Animal  
Hospital

**REFERRING VET**

Dr. Alexander

**INVOICE**

32461

**DATE**

8.21.23

CANINE CARDIAC PARAMETERS	MR VMAX (m/s)	TR VMAX (m/s)	LA/AO (Boon method)	LA/AO (Heart Base; Swe)	FS (%)	EF (%)	EPSS (cm)
NORMAL PARAMETER	4.5-5.5	<2.7	1.3	<1.6	28-40	40-100	<0.6
PATIENT	NA	NA	NM	1.2	39	70	NM
CANINE CARDIAC PARAMETERS	HR (BPM)	AV VMAX (m/s)	PV MAX (m/s)	BODY WEIGHT (kg)	LA 2D short axis Base view (cm)	LVIDd Avg; 2D and m-mode short axis (cm)	LVIDs Avg; 2D and m-mode short axis (cm)
NORMAL PARAMETER	50-100	0.7-1.7	0.7-1.6	BELOW	BELOW	BELOW	BELOW
PATIENT	92	0.8	1.0	30.0	2.6	3.9	2.6
*Normal chamber parameters expressed as a mean value (SD)				3	1.27 (5.3)	2.46 (2.46)	1.36 (5.5)
<b>BODY WEIGHT DEPENDENT PARAMETERS</b>				5	1.40 (4.5)	2.74 (5.2)	1.60 (4.7)
*Note: All measurements based upon multi-modal images and methods. An average value is reported.				10	1.50 (3.8)	3.27 (3.5)	2.06 (3.1)
				15	1.83 (2.0)	3.71 (2.4)	2.43 (2.1)
				20	2.02 (1.9)	4.14 (2.2)	2.80 (2.0)
				25	2.18 (2.4)	4.48 (2.9)	3.10 (2.5)
				30	2.33 (3.3)	4.83 (3.9)	3.39 (3.4)
				35	2.48 (4.3)	5.17 (5.0)	3.69 (4.5)
				40	2.62 (5.2)	5.48 (6.1)	3.96 (5.4)
				50	2.88 (7.1)	6.07 (8.3)	4.46 (7.4)

Adapted from June Boon, Veterinary Echocardiography, 1998  
 Rishniw M and Hollis NE, J Vet Intern Med 2000; 14:429-435  
 Hansson et al, Vet Rad and Ultrasound 2002  
 Bonagura et al. Echocardiography: principles of interpretation, Vet Clin North Am 15:1177, 1995

## INTERPRETATION OF THE FINDINGS & FURTHER RECOMMENDATIONS

The cause of the symptoms is large volume pericardial effusion. The cardiac structure and function are normal in this patient, with no evidence of structural disease. The patient does appear volume underloaded and fluid therapy is warranted. The patient is in cardiac tamponade (ascites, collapse of the RA), and a pericardiocentesis is necessary ASAP. No definitive tumors are seen in this study; however, it is important to note that small masses on the external surface of the heart are extremely easy to miss. Advanced imaging should be considered.

Assuming the effusion is hemorrhagic (most likely), the two most common causes of pericardial effusion in older large breeds dogs are idiopathic and neoplastic. Less commonly, pericarditis (an inflammatory condition), a left atrial tear, or a bleeding disorder should also be considered. Idiopathic by definition means that a cause cannot be found. If diagnosed (a rule out diagnosis), the long-term prognosis with idiopathic effusion has the potential to be fair.

Regarding neoplasia, the most common types of cardiac cancer-causing pericardial effusion include hemangiosarcoma (HSA), chemodectoma, or mesothelioma. The prognosis varies a great deal depending on the underlying type of cancer. Based on the findings of today's echocardiogram, there is not definitive evidence of a clear tumor. Consider referral to a local Cardiologist for advanced echocardiography and/or thoracic CT scan. If declined, a reevaluation is recommended in the next 1-2 months, as often small masses will become apparent in that period of time. Even without definitive identification, one should always be suspicious for neoplasia given the signalment.

Given evidence of tamponade, a pericardiocentesis is necessary ASAP for both diagnostic and therapeutic purposes in this case. If this is not ideal at your facility, referral to a multi-specialty center is highly recommended for the procedure. Once a sample is obtained, follow up diagnostics to screen for underlying causes is recommended to determine treatment/follow up plan (fluid cytology, etc.).

Regardless of underlying cause, it is impossible to predict if and when pericardial effusion will reoccur. Some patients with idiopathic effusion need to be tapped between 1 to 3 times then never again. Other patients may experience frequent recurrence with either HSA or idiopathic disease. If the effusion reoccurs frequently, a surgical procedure called a pericardiectomy can be discussed.

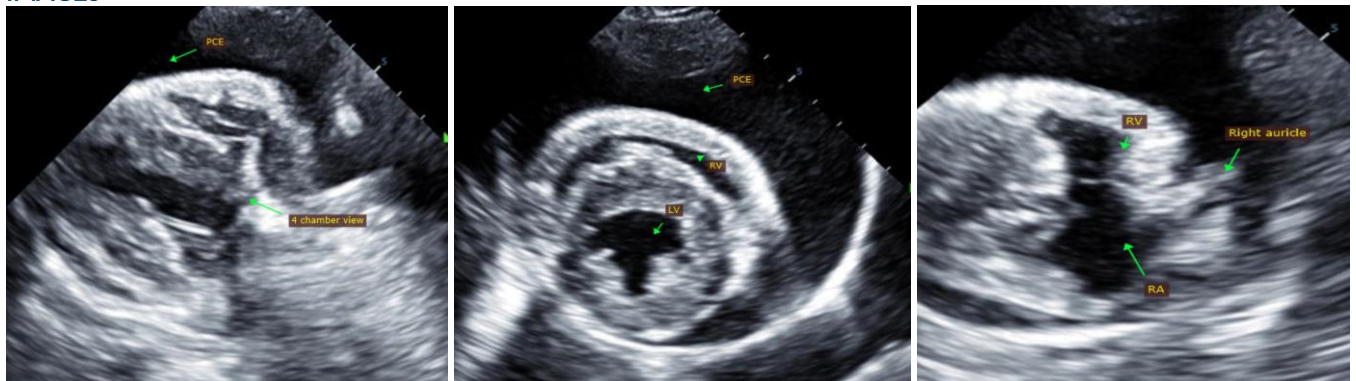
No cardiac medications are clearly indicated at this time. Over the counter herbal supplement Yunnan Baiyao (aka Yunnan Paiyao) may help decrease risk of bleeding, however true benefit is speculative (1 capsule PO BID). Please monitor at home for signs of recurrent pericardial effusion including pale gums, difficulty breathing, lethargy/collapse, exercise intolerance, abdominal distention, vomiting, and/or inappetence. If you notice any of these symptoms, patient should be evaluated immediately by a veterinarian.

## PLAN

Immediate pericardiocentesis should be performed with consideration of fluid therapy, ECG monitoring and hospitalization. Full systemic evaluation is recommended.

A recheck echocardiogram is recommended based upon results of discussed pericardiocentesis and work up. If the patient does well, reassess AV groove in 1-2 months.

## IMAGES



**The information and recommendations provided are based on the images presented by the referring veterinarian. No evaluation can be communicated regarding pathology that was not visible in the image/video clips provided.**

Thank you for this referral. This report was generated using transcription software, and minor dictation errors may be present. If the clinical or image interpretation does not parallel your findings or if I can be of any further assistance, please contact me.

**Maggie Machen Lamy, DVM**  
**Diplomate of the American College of Veterinary Internal Medicine (Cardiology)**  
**info@sonopath.com**